

# Histomorphological Features of Placenta in Pregnancy Complicated with Intrauterine Growth Retardation

Nitin Gupta, Arvind Khajuria

## Abstract

The present study was conducted in the Post Graduate Department of Pathology, Acharya Shri Chander College of Medical Sciences and Hospital, Sidhra, Jammu and included 35 IUGR and 30 normal placentas for one year. Histomorphological evaluation of placenta from IUGR fetuses can supplement clinical knowledge of the cause of IUGR and also help us to evaluate perinatal mortality and morbidity. An assessment of placental pathology is useful for couples in resolving issues arising from pregnancy complications including perinatal loss and it also guides for future investigations and interventions for subsequent pregnancies. Our institution is a tertiary care hospital where patients come from all over the Jammu region. Histomorphological analysis of placenta in IUGR pregnancies can thus provide us with fairly good estimate of relation between clinical profile of the mother and IUGR placentas.

## Key Words

IUGR, Placenta, Pregnancy, Histomorphology

## Introduction

Intrauterine growth retardation (IUGR) is a failure to achieve the growth potential of a fetus that is promised by the genetic constitution and environmental influences endogenous to the pregnancy. Fetal growth retardation is the second leading cause of perinatal morbidity and mortality, followed only by prematurity. Intrauterine growth retardation is a complicated placental vascular disease resulting in low birth weight, preterm delivery and increased perinatal morbidity and mortality. The infant born with IUGR is recognized as having an increased risk of in utero mortality, neonatal morbidity and mortality and as well as long term neurological complications. The neonatal mortality rate for IUGR infants born at 38 weeks was 1% compared with that of 0.2% in those with appropriate birth weights (1). The causes of IUGR can be of maternal, placental or fetal origin. Placentas of IUGR pregnancies show many histomorphological abnormalities. The weight of IUGR placentas is less than the normal control placenta. In microscopic study of placenta the parameters usually evaluated are non-inflammatory changes of the amnion, acute inflammatory changes, infarction, intervillous thrombosis, chorionic

villitis, hemorrhagic endovasculitis, placental intravascular thrombi, syncytial knots, perivillous fibrin deposition and fibrinoid necrosis, basement membrane thickening, erythroblastosis and villous edema (2).

## Material and Methods

This prospective study was conducted over a period of one year. A total of 65 pregnant women were included in the study after following the selection criterion mentioned ahead. 35 placentas of diagnosed cases of pregnancies complicated by intrauterine growth retardation (IUGR) of more than or equal to 28 weeks of gestation were included in this study. 30 placentas of normal pregnancies were included as controls where the mother had no significant antenatal history. The cases of eclampsia, preterm and twin pregnancies were excluded from the study. In each case, detailed clinical information about the antenatal history and examination of the mother was obtained with special reference to maternal weight gain during pregnancy, history of chronic diseases e.g tuberculosis, diabetes mellitus, hypertension, heart disease, obesity, Rh incompatibility, ABO incompatibility, smoking, alcoholism, infection (TORCH). Ultrasound

From the Department of Pathology, ASCOMS, Sidhra, Jammu-J&K India

Correspondence to : Dr. Arvind Khajuria Professor and Head, Department of Pathology, ASCOMS Sidhra, Jammu-J&K

findings were obtained from clinical case sheets and recorded. The clinical information of the fetus was obtained with special reference to birth weight, head circumference, crown to rump length, apgar score, birth weight to placental weight ratio. Ponderal index was calculated by formula: birth weight (g)/length (cm).

The placentas received by the department of pathology were properly labelled, numbered and allowed to fix in 10% buffered formalin for 24 hours and detailed gross examination of placenta, membranes and cord was carried out. The histopathological sections were taken from all cases and controls and were processed and stained routinely with hematoxylin and eosin (H&E) A detailed histopathological examination of H&E sections were carried out and the lesions were categorized as follows:

1. Lesions of fetal membranes
2. Lesions of umbilical cord
3. Lesions of placenta

## Results

The age of the patients in study group ranged from 17-36 years. While in the control group the age range was 19-34 years. The patients in study and control groups were similar in age and gestational duration (>28 weeks). (Table 1)

**Clinical profile of mothers and newborn with IUGR pregnancy:** A detailed clinical history was elicited from each woman of both study and control group. All the mothers of control group gained 6-11 kg during pregnancy; while weight gain was <6 kg during pregnancy; while weight gain was <6 kg in % mothers of IUGR babies. The study group included 27 (77.1%) IUGR live births and 8 (22.8%) IUGR- intrauterine deaths (IUD) The clinical conditions seen in association with IUGR pregnancies are shown in Table 2. In the present study, most common maternal condition in IUGR were anemia and pregnancy induced hypertension (PIH) being present in 14 and 13 cases respectively.

**Placental weight:** Majority (29/35; 82.9%) of the placentas of the study group weighed < 300g; and none of these placentas weighed more than 400g. . While in the control group, most placentas (16/30; 53.3%) weighed more than 400g. In the present study, most of the IUGR placentas had markedly low weight. These was a statistically significant difference between the weight of IUGR and control placentas ( $p < 0.001$ ). In the study group, 26/35 (74.3%) placentas measured 18 cm in diameter. However only 1/30 (3.3%) normal placenta was 18 cm. The p value was <0.001.

**Placental thickness:** Thickness of the placentas was measured in the center. In the study group, 19 of 35 placentas were more than 3 cm thick (54.3%). Whereas

only 6 of 30 control placentas had thickness of more than 3 cm ( $p < 0.01$ ). Though the IUGR placentas were smaller and lighter but they were more in thickness as compared to control placentas.

**Placental infarction:** Grossly, infarction was divided in three categories- mild, moderate and extensive involving 0-5%, 5.1-10% and >10% of placental area respectively. On gross examination, majority of the IUGR placentas (18/35; 51.4%) showed extensive infarction. The largest infarct in IUGR involved 72% of the surface area. This baby died in utero. Moderate degree of placental infarction was also more common in IUGR (13/35) as compared to control placentas (7/30). Most of the normal placentas showed infarction involving <5% area. The IUGR placentas had more extensive infarction as compared to controls ( $p < 0.001$ ). **Perivillous Fibrin:** In our study, gross perivillous fibrin (PVF) deposition involving less than 5% area was seen in 26/35 (74.3%) cases of IUGR placentas and 27/30 (90%) of normal placentas. While massive PVF deposition involving more than 30% of placental area was observed in 7/35 (20%) placentas of the study group. None of the control placentas showed massive PVF. Massive PVF was more commonly observed in IUGR placentas

**Microscopic Features of IUGR Placenta:** **Infarction:** Microscopically, infarction was divided in three categories- mild (involving 0-5% of villi), moderate (5.1-10% villi) and extensive (>10% villi). Extensive infarction was more frequently observed in IUGR placentas. Extensive infarctions involving more than 10% of villi were seen in 9/35 (25.7%) IUGR. None of the control placentas showed extensive infarction. Moderate infarction was also more frequently associated with IUGR placentas. The p value was statistically significant ( $p < 0.01$ ).

**Perivillous Fibrin:** The distribution of PVF was divided in two categories, involving ? 30% of villi and > 30% of villi respectively. Majority of the placentas (30 cases and 29 controls) showed PVF deposition of ? 30% villi. Only 5/35 (14.3%) IUGR and 1/30 (3.3%) of normal placenta showed PVF involving > 30% ( $p < 0.5$ ). Though massive PVF was seen only in IUGR placentas and none of the control placentas, there was no statistically significant difference in two groups.

**Syncytial Knotting:** Syncytial knotting involving ?30% villi was seen in 7/35 (20%) of the study group and 20/30 (66.7%) of control group. excessive knotting of > 50% villi were seen more frequently in IUGR (12/35; 34.3%) than control placentas (1/30; 3.3%). This difference was statistically highly significant ( $p < 0.001$ ).

**Villous Vascularity:** In the present study,

**Table 1. Age Distribution**

Maternal Age (years)	No. of Cases	No. of Controls
<20	3	1
20-25	17	16
26-30	10	11
31-35	3	2
>35	2	0
<b>Total</b>	<b>35</b>	<b>30</b>

**Table 2. Associated Maternal Clinical Conditions In The Study Group**

Clinical Diagnosis	No. of Cases	Percentage(%)
PIH/HT	13	(37)
Anemia	14	(40)
Oligohydramnios	7	(20)
Anemia+HT	4	(11.4)
TORCH+	2	(5.7)
Rh-	1	(2.8)

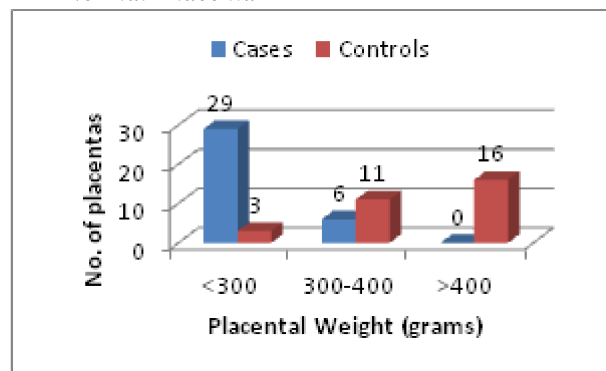
hypovascular villi were defined as villi, which contain less than or equal to one vessel. More than 5% of hypovascular villi were observed more frequently in IUGR placentas (20/35) as compared to the control placentas (3/30); p value was <0.001. More than 5% of hypervascular villi were seen in 9/35 (25.7%) cases and 13/30 (43.3%) controls. No statistically significant difference was found between occurrence of hypervascular villi in the study and the control group (p < 0.5).

**Fibrotic Villi:** IUGR placentas showed increase in collagenisation of villi or fibrotic villi. Increase in fibrotic villi was seen more commonly in IUGR placentas (17/35). Whereas only 3/30 normal placentas showed fibrotic villi of >3%. In our study fibrotic villi were more frequently present in IUGR placentas (p < 0.001).

**Basement Membrane Thickening & Cytotrophoblastic Hyperplasia:** Basement membrane thickening was taken as significant when present in >2% of villi. In the study group, 23/35 (65.7%) placentas showed thickening of basement membrane. While in controls, only 3/30 (10%) showed this lesion (p < 0.01). Cytotrophoblastic hyperplasia (CTHP) was observed in 28/35 (80%) of the study group and 8/30 (26.7%) of control group. CTHP was more common in IUGR placentas than controls (p < 0.001).

**Edematous villi:** Occasional edematous villi were observed in both the groups. But increased number of edematous villi was seen in IUGR placentas. The edema

**Fig 1. Comparison of Placental Weight in IUGR and Normal Placenta**



was also present to greater extent in IUGR placentas as compared to controls. Twenty-one out of 35 (60%) IUGR and 5 out of 30 control placentas showed > 3% edematous villi (p < 0.01).

**Fibrinoid Necrosis:** In present study, fibrinoid necrosis involving >5% terminal villi were taken as abnormal. In the study group, fibrinoid necrosis of 5% of terminal villi was seen in 19 (54.3%) cases. While in control placentas, the lesion was seen in 11 (36.7%) placentas. However, fibrinoid necrosis was more commonly present in IUGR placentas but the difference was not significant statistically. (p < 0.5)

### Discussion

In our study, the age of the patients in study group ranged from 17-36 years (25.49±3.4 years). While in control group the age range was 19-34 years (25±3.4 years). The controls in the study were age matched and of similar gestational age of 28. In the present study, majority of the placentas (82.9%) of the study group weighed less than 300 grams and none of the placentas weighed more than 400 grams. While in the control group, only 3/30 (10%) placentas weighed <300 grams in our study, most of the IUGR placentas were smaller and lighter in comparison to controls. There was a statistically significant difference between the weight of IUGR and control placentas (p<0.001). Similarly, 84% IUGR placentas in the study of Mardi *et al* (3) weighed less than normal. 16% (12/75) weighed >400g.). In the current study, most of the IUGR placentas 26/35 (74.3%) were >18 cm in diameter. Only 1/30 (3.3%) placenta of control group was >18 cm. The p value was <0.001. Therefore, IUGR placentas were smaller size as compared to control placentas. Thickness of the placentas was measured in the center. In the study group, the placental thickness was >3cm in 19/35 (54.3%). Whereas only 6/30 control placentas had thickness of >3cm. (p<0.01). Biswas & Ghosh (4) also observed that the placentas of IUGR

difference in frequency of infarction in IUGR and normal term placentas. In the current study, smaller degrees of microscopic infarcts were present in both the groups. But extensive infarction was more frequently observed in IUGR placentas. Extensive infarction involving >10% villi was seen in 9/35 IUGR and 0/30 control placenta. The p value was statistically significant ( $p < .01$ ). Therefore extensive infarction was more frequently present in IUGR placentas than controls. Mardi *et al* [3], in their study also found that microscopic infarcts were more commonly present in IUGR placentas. In their study, the infarcts were present in 56% of IUGR and 12% of normal placentas. ( $p < 0.001$ , highly significant)

In our study, gross perivillous fibrin (PVF) deposition was seen involving less than 5% of placental area in 26/35 (74.3%) cases of IUGR placenta and 27/30 (90%) of control placentas. However massive PVF deposition involving >30% of placenta was seen more frequently in IUGR placentas. Massive PVF deposition was observed in 7/35 (20%) of study group whereas none of the control placentas showed massive PVF ( $p < 0.1$ ). Mardi *et al* (3) noted intervillous fibrin deposition involving 6-10% placental area in 4% of both study and control groups, but massive fibrin deposition involving more than 10% placental area was seen in 20% placentas of study group and 0% of controls. Massive fibrin deposition was more frequently observed in IUGR placentas as compared to controls ( $p < 0.001$ ). In the present study, 30/35 IUGR placentas and 29/30 controls placentas showed microscopic PVF deposition involving >30% of villi. 5 (14.3%) IUGR and only 1 (3.3%) control placentas showed PVF deposition involving more than 30% villi. Mardi *et al*, (3) also found that microscopic deposition of perivillous fibrous was more in IUGR placentas (64%) than non-IUGR placentas (12%). Nigam *et al* (7) also observed deposition of perivillous fibrous was more in IUGR placentas than non-IUGR placentas. Kotgirwar *et al* (5) also observed increased perivillous fibrinoid deposition in 16.7% of IUGR placentas

In the present study, increased knotting was observed in placentas of IUGR pregnancies as compared to control placentas. Excessive knotting >50% of villi was observed in 12/35 (34.3%) IUGR placentas and in 1/30 (3.3%) of control placentas. While syncytial knotting in >30% villi was seen in 7/35 (20%) of study group and 20/30 (66.7%) of control group. The difference between knotting of villi in cases and control placentas was statistically highly significant ( $p < 0.001$ ). Therefore markedly increased syncytial knotting was more frequently present in IUGR placentas as compared to normal placentas. Mardi *et al* (3) also found increased syncytial knots in IUGR placentas

babies were thicker and smaller than normal placentas.

In the current study, on gross examination of the placenta, we observed that extensive infarction involving >10% of placental area was more frequent in IUGR placentas. Extensive infarction was present in 51.4% (18/35) IUGR whereas none of the control placentas showed extensive infarction ( $p < 0.001$ ). Thus, extensive infarction was present only in IUGR placentas. Moderate degrees of placental infarcts were also more commonly present in IUGR (13/35) than control (7/30) placentas. The smaller infarcts involving <5% surface area were more common in normal placentas (23/30) as compared to cases (4/35). Mardi *et al* (3) also observed the incidence of infarction involving 6-10% of placental area to be 12% in IUGR placentas; while extensive infarcts (>10% of area) were seen in 4% of the IUGR cases. None of the placentas of control group showed gross infarction. Hence infarction was more common in IUGR placentas than controls. Kotgirwar *et al* (5) observed increased placental infarction in their study. In contrast to these studies and our observations, Sato *et al* (6) did not find any significant difference than control placentas. In the series of Mardi *et al* (3), syncytial knots of 30-50% villi was observed in 16% of IUGR placentas while marked syncytial knotting of more than 50% villi was seen in 48% of those placentas. None of the control placentas showed increase knotting in more than 30% of villi ( $p < 0.001$ ). Biswas *et al* (8) also observed increase number of syncytial knots in IUGR placentas than that of the control placentas. Kotgirwar *et al* (5) in their study observed increased syncytial knots in 60% of IUGR placentas

In the present study, more than 5% of hypovascular villi were present in IUGR placentas (20/35) to greater extent as compared to non-IUGR placentas (3/30) ( $p < 0.001$ ). No statistically significant difference was found between the occurrence of hypervascular villi in the study and control group. more than 5% of hypervascular villi were seen in 25.7% (9/35) cases and 43.3% (13/30) controls ( $p < 0.5$ ). Mardi *et al* (3) too observed higher number of hypovascular/ avascular villi in IUGR placentas than controls. Hypovascular villi were seen in 24/75 (32%) placentas of IUGR infants; while none of the controls showed hypovascular/ avascular villi ( $p < 0.01$ ). Biswas *et al* (8) also observed large number of hypovascular/ avascular villi in IUGR placentas.

In the present study, IUGR placentas showed increased frequency of fibrotic villi ( $p < 0.001$ ). Fibrotic villi constituting >3% of all villi were observed in 17/35 IUGR and 3/30 control placentas. Similarly, Mardi *et al* (3) observed fibrotic villi in 56% of IUGR placentas. While in control group none of the placentas (0/25) showed

fibrotic villi ( $p < 0.001$ ) which was highly significant

In the study group, 23/35 (65.7%) placentas showed basement membrane thickening. While in control group, basement membrane thickening was seen in 3/30 (10%) placentas ( $p < 0.01$ ). Hence, basement membrane thickening was more frequently observed in IUGR placentas than controls. Mardi *et al* (3) found basement membrane thickening of  $>2\%$  terminal villi in 12/75 (16%) IUGR placentas. While none of the villi in control group showed basement membrane thickening. In current study, CTHP was present in 80% (28/35) of the study group; whereas only 26.7% (8/30) control placentas showed this lesion. Thus CTHP was more commonly present in IUGR placentas than control placentas ( $p < 0.001$ ). Similarly, Mardi *et al* (3) also observed cytotrophoblastic hyperplasia to be more common in IUGR placentas (44%) than controls (0%) ( $p < 0.001$ ). The incidence of CTHP in IUGR placentas was also increased in other studies.

In the current study, occasional edematous villi were observed in both the groups. But more numbers of edematous villi were seen in IUGR placentas. The degree of villous edema in IUGR placenta was also present to the greater extent. 21 of 35 (60%) IUGR and 5 of 30 control placentas showed  $>3\%$  edematous villi.  $p$  value was  $<0.01$ . Vedmedovska *et al* (9) and Pereira *et al* (10) also observed increased number of edematous villi in IUGR patients in their respective studies.

In present study, fibrinoid necrosis involving 5% terminal villi were taken as significant. In study group, fibrinoid necrosis of  $>5\%$  terminal villi was seen in 19/35 (54.3%) cases; while in control group, the lesion was seen in 11/30 (36.7%) placentas. Though fibrinoid necrosis was more common in IUGR placentas but the difference was not statistically significant. ( $p < 0.5$ ) Mardi *et al* (3) also found increased fibrinoid necrosis in IUGR placentas (20%) as compared to control placentas (4%). Shams *et al* (11) in their study found fibrinoid necrosis was statistically significant in IUGR placentas due to diabetic mothers as compared to the control group i.e. 13.98% vs. 4.02%, respectively. Nahar *et al* (12) observed fibrinoid necrosis in 80% of IUGR placentas due to pregnancy induced hypertension.

### Conclusion

Our study concludes that fetus, placenta and mother are so closely interconnected, proper nutrition of the mother is very important to expect a healthy baby as outcome. The multitude of gross and microscopic changes in IUGR placentas point towards uteroplacental vascular

insufficiency, which result in restriction of the blood flow to the fetus and hence lead to intrauterine growth retardation. It is important to recognize the lesions for effective management of subsequent pregnancies.

### References

1. Cunningham FG, Levono K, Bloom S, *et al*. Fetal Growth Disorders. *Williams Obstetrics* 2005; 22:895.
2. Gunyeli I, Erdemoglu E, Ceylaner S, *et al*. Histopathological analysis of placental lesions in pregnancies complicated with IUGR and stillbirth in comparison with noncomplicated pregnancy. *J Turkish German Gynecol Assoc* 2011;12:75-79.
3. Mardi K, Sharma J. Histopathological evaluation of placentas in IUGR pregnancies. *Indian J Pathol Microbiol* 2003;46(4):551-54.
4. Biswas S, Ghosh SK. Gross morphological changes of placentas associated with intrauterine growth restriction of fetuses: a case control study. *Early Hum Dev* 2008 ;84(6):357-62.
5. Kotgirwar S, Ambiyae M, Athavale S, *et al*. Study of gross and histomorphological features of placenta in intrauterine growth retardation. *J Anat Soc* 2011;60:37-40.
6. Sato Y, Benirschke K, Marutsuka K, *et al*. Associations of intrauterine growth restriction with placental pathological factors, maternal factors and fetal factors; clinicopathological findings of 257 Japanese cases. *Histol Histopathol* 2013 ;28(1):127-32.
7. Nigam J, Misra V, Singh P, *et al*. Histopathological study of placentae in low birth weight babies in India. *Ann Med Health Sci Res* 2014;4(Suppl 2):S79-83
8. Biswas S, Adhikari A, Chattopadhyay JC, Ghosh SK. Histological changes of placentas associated with intra-uterine growth restriction of fetuses: a case control study. *Nepal Med Coll J* 2012;14(1):18-24.
9. Vedmedovska N, Rezeberga D, Teibe U, Melderis I, Donders GG. Placental pathology in fetal growth restriction. *Eur J Obstet Gynecol Reprod Biol* 2011 ;155(1):36-40.
10. Pereira L, Petitt M, Fong A, *et al*. Intrauterine growth restriction caused by underlying congenital cytomegalovirus infection. *J Infectious Diseases* 2014 ;209(10):1573-84
11. Shams F, Rafique M, Samoo NA, Irfan R. Fibrinoid necrosis and hyalinization observed in normal, diabetic and hypertensive placentae. *J College of Surgeons Physician-Pakistan* 2012;22(12):769-72
12. Nahar L, Nahar K, Hossain MI, *et al*. Placental changes in pregnancy induced hypertension. *Mymensingh Medical J* 2013;22(4):684-93